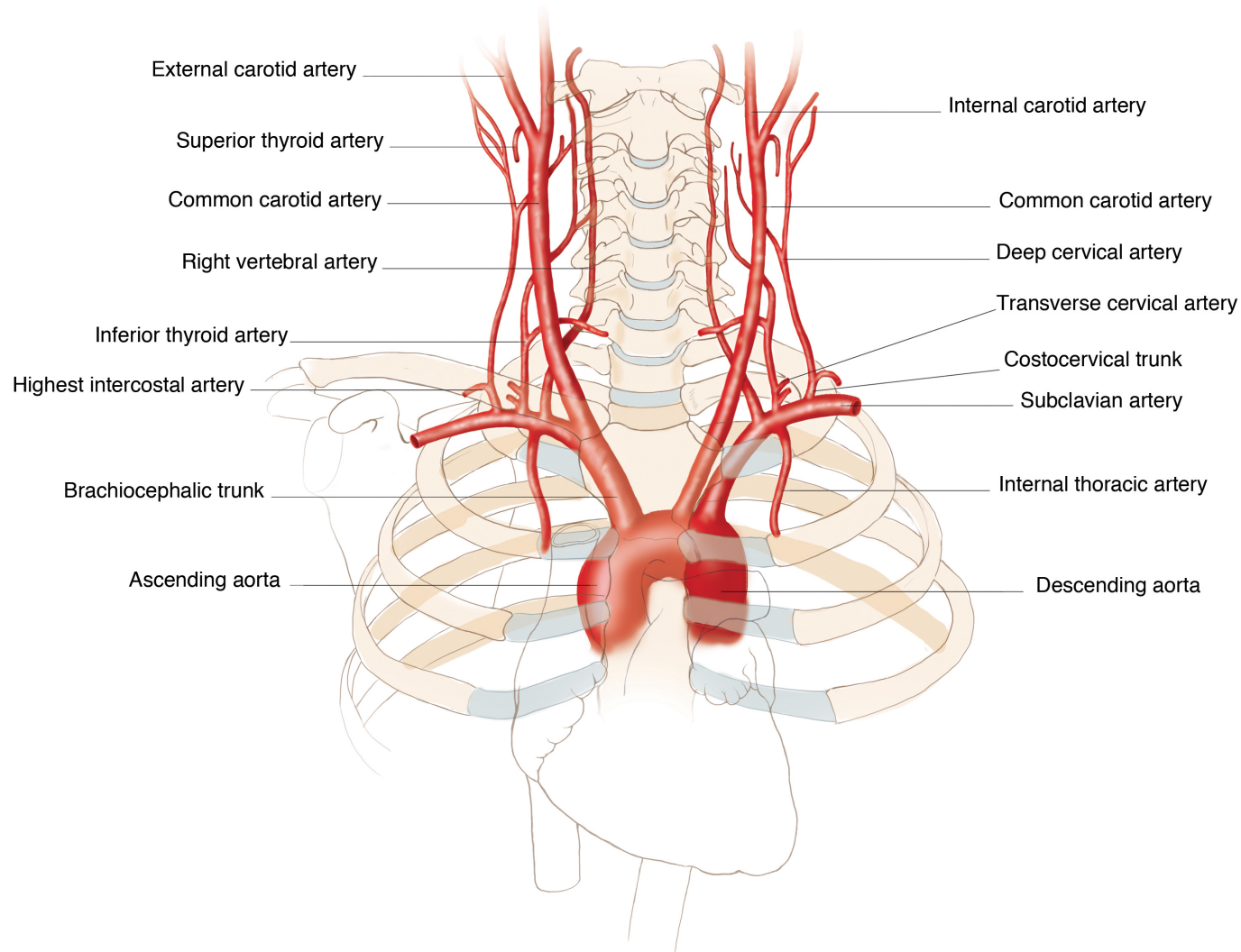

How to enter ascending aorta?

Ask patient to take a deep breath and push the wire

OR

Use a JR4 or a pigtail catheter and turn clockwise to orient the wire through ascending aorta and push it

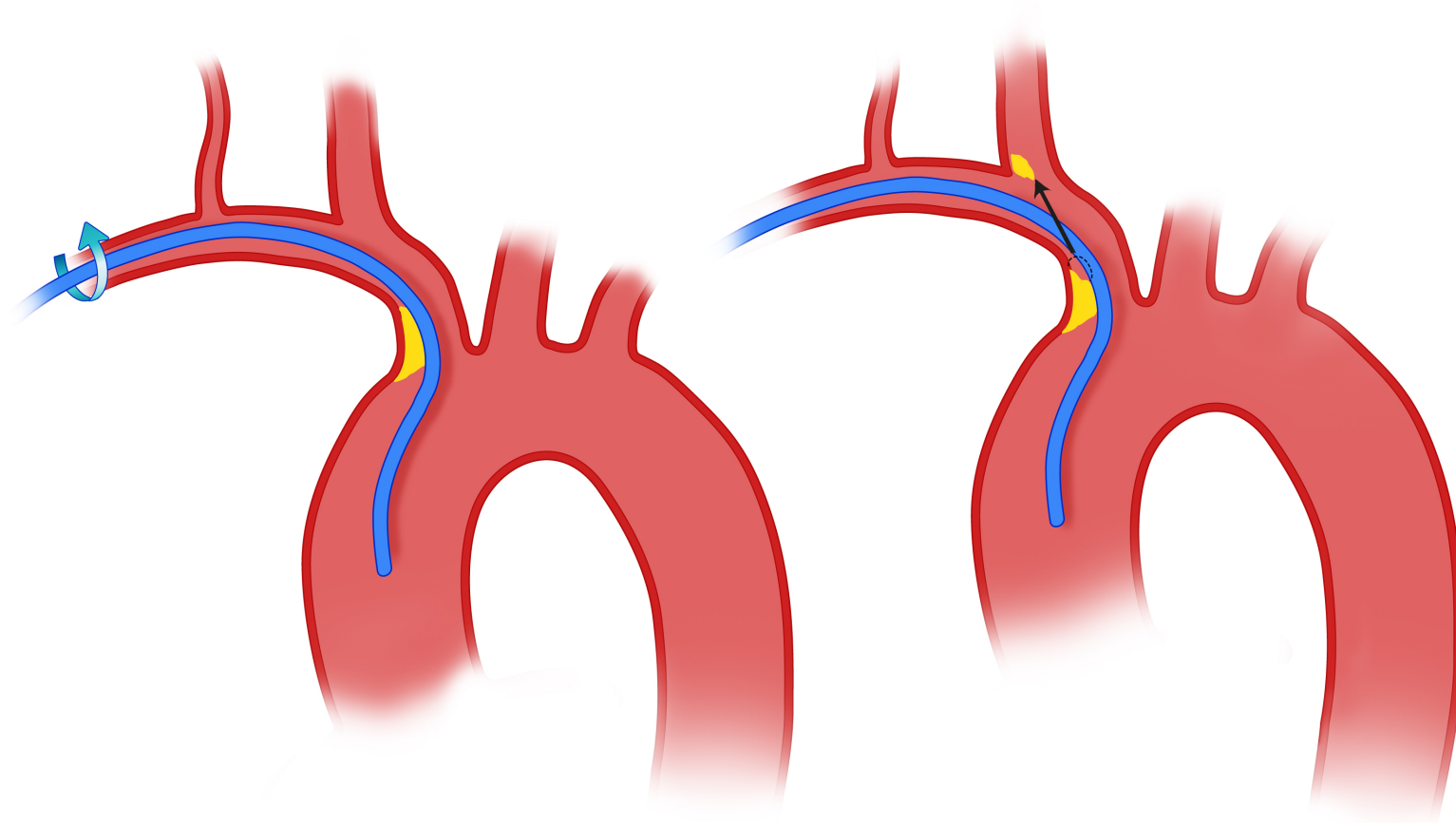


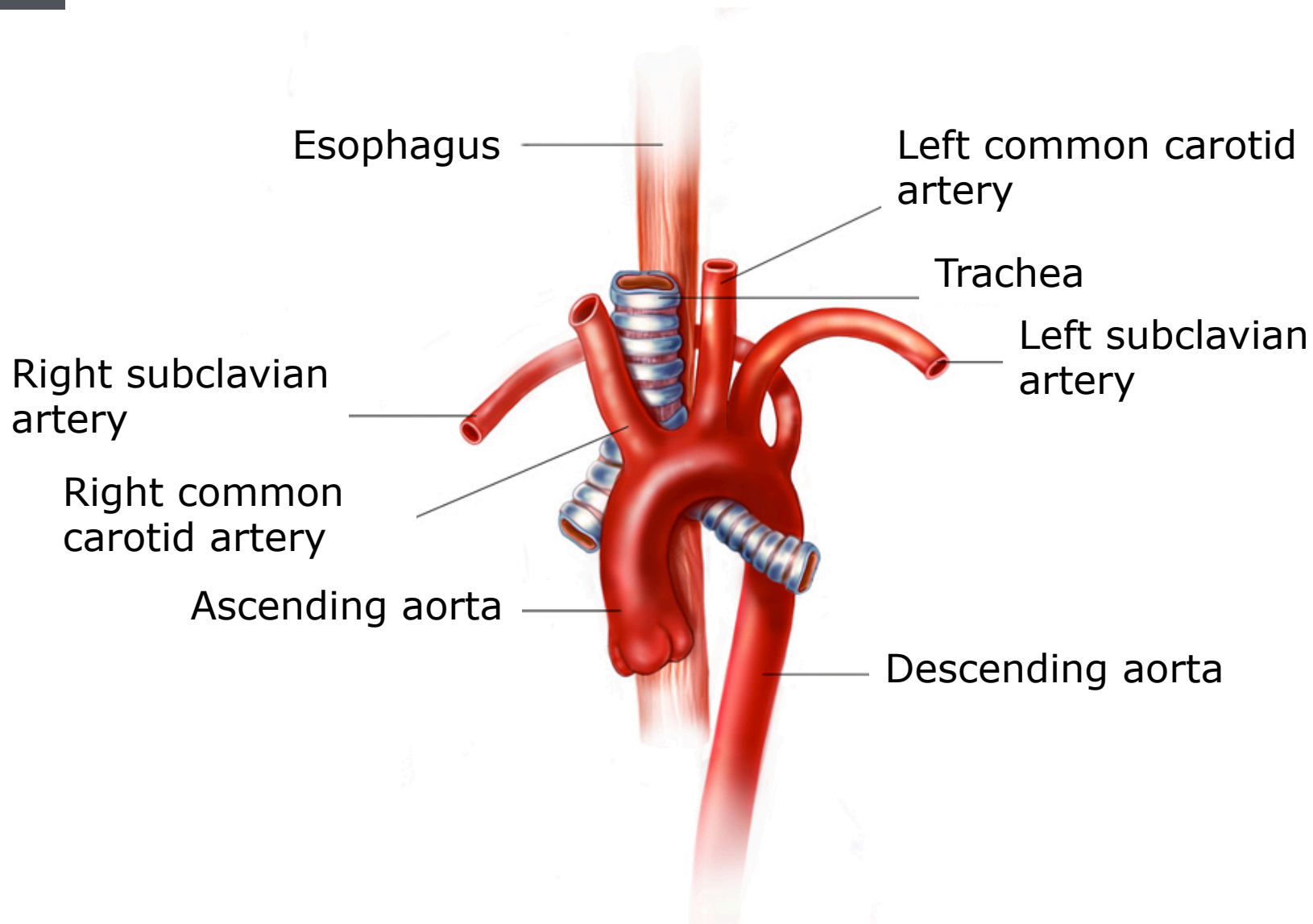
Sub-clavian tortuosity predictive factors

Old age

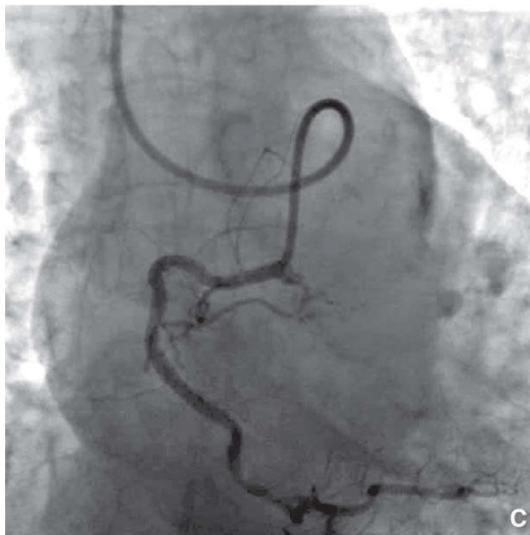
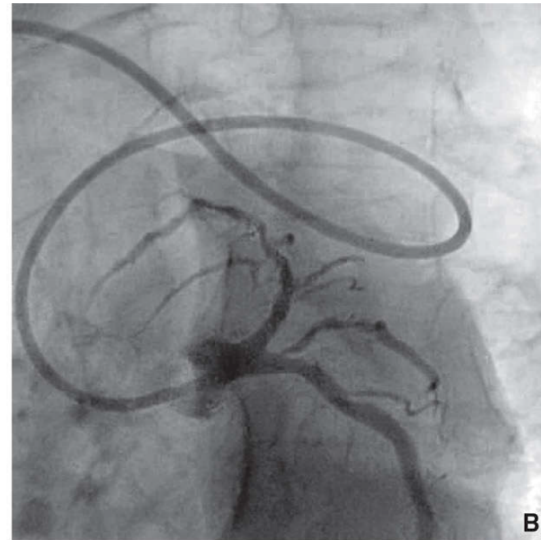
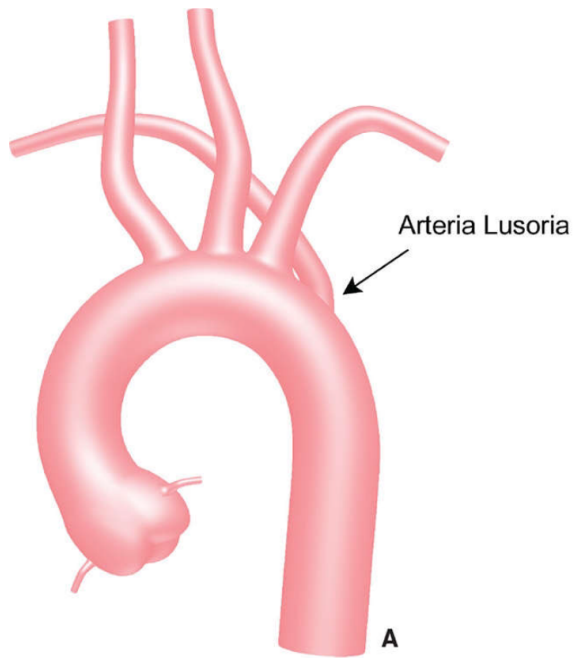
Hypertension

Woman





Arteria Lusoria





Subclavian navigation - summary

Anatomical variations more frequent in old woman and HTA patients

Deep breathing to enter ascending aorta

Use hydrophilic wire to cross but always under fluoroscopy

Avoid aggressive manipulation to prevent stroke risk